



RESENTING CLINICAL SIGNS

DATE History: Trouble breathing, gasping, coughing. No murmur. Rads - trachea slightly dorsally deviated. History of seizures.

3/29/22

ECHOCARDIOGRAPHIC FINDINGS

PERFORMED BY: 2D, M-mode, and Doppler study.

Dr. Meredith Swart Left atrial size is normal. The mitral valve appears normal, though trace mitral regurgitation is present. Left ventricular dimensions are normal. Left ventricular systolic function is hyperdynamic. The aorta and aortic valve appear normal. Right atrial and right ventricular dimensions are normal. The tricuspid valve is normal. The pulmonary artery and pulmonic valve are normal. No shunting lesions are visualized. No pericardial effusion is seen.

INTERPRETED BY

Keith Blass, DVM,
MS, DACVIM
(Cardiology)

LA - 21.5 mm
LVIDd - 19.7 mm
LVIDs - 10.8 mm
FS - 45%
RVOT - 0.67 m/s

PATIENT

Boomer Nunziantte

ASSESSMENT/RECOMMENDATIONS

Normal echocardiogram

SPECIES

Canine

This examination demonstrates no evidence of structural heart disease, as trace mitral regurgitation can be considered a normal physiologic variant. As such, no reason for Boomer's respiratory clinical signs is appreciated in the image set.

BREED

Maltese Mix

No therapy is recommended based on Boomer's echocardiogram.

A recheck echocardiogram is recommended if new physical exam and/or clinical abnormalities suggestive of cardiac dysfunction develop.

SEX

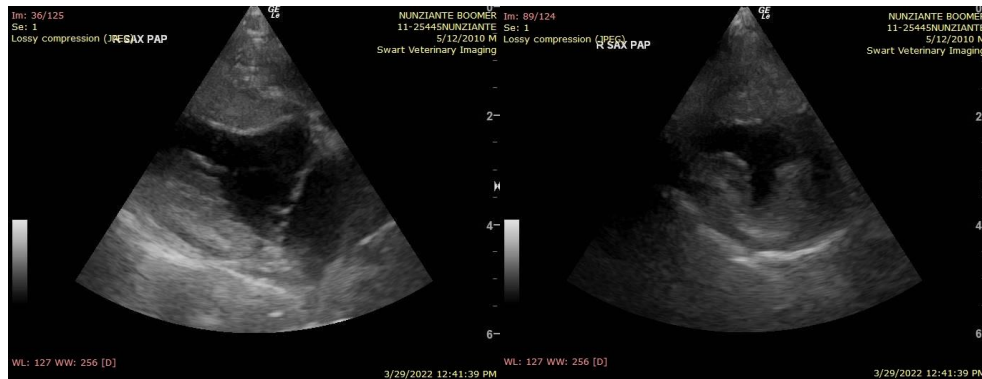MN

AGE

11 y

WEIGHT

10 lb



HOSPITAL NAME

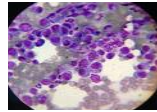
Swart Veterinary
Imaging

The information and recommendations provided are based on the images presented by the referring veterinarian. No evaluation can be communicated regarding pathology that was not visible in the image/video clips provided.

Thank you for this referral. If the clinical or image interpretation does not parallel your findings or if I can be of any further assistance please contact me.

REFERRING VET

Dr. Swart



DATE Keith Blass, DVM, MS, DACVIM (Cardiology)

KeithBlass@gmail.com

3/29/22 631-804-5754

PERFORMED BY:

Dr. Meredith Swart

INTERPRETED BY

Keith Blass, DVM,
MS, DACVIM
(Cardiology)

PATIENT

Boomer Nunzianta

SPECIES

Canine

BREED

Maltese Mix

SEX

MN

AGE

11 y

WEIGHT

10 lb

HOSPITAL NAME

Swart Veterinary
Imaging

REFERRING VET

Dr. Swart